

## FUNCTIONAL OUTCOME OF AC JOINT DISLOCATION TREATED WITH ARTHROSCOPIC ASSISTED DOG BONE BUTTON TECHNIQUE

Kurmana VamsiKrishna<sup>1</sup>, Balijepalli Saiphani Chandra<sup>2</sup>, Chamalla PhalgunaDeepak<sup>3</sup>, SantoshBabu Miryabelli<sup>4</sup>

Received : 10/09/2023

Received in revised form : 05/10/2023

Accepted : 16/10/2023

**Keywords:**

Ac joint dislocation, arthroscopy, dog bone button technique

Corresponding Author:

**Dr. santoshbabu miryabelli**

Email: msbmbbs2k6@gmail.com

DOI: 10.47009/jamp.2023.5.5.317

Source of Support : Nil,

Conflict of Interest: None declared

*Int J Acad Med Pharm*

2023; 5 (5); 1617-1620



<sup>1</sup>Assistant Professor, Great Eastern Medical School and Hospital, Ragolu, Srikakulam, Andhra Pradesh, India.

<sup>2</sup>Assistant Professor, Great Eastern Medical School and Hospital, Ragolu, Srikakulam, Andhra Pradesh, India.

<sup>3</sup>Assistant Professor, Great Eastern Medical School and Hospital, Ragolu, Srikakulam, Andhra Pradesh, India.

<sup>4</sup>Associate Professor, Great Eastern Medical School and Hospital, Ragolu, Srikakulam, Andhra Pradesh, India.

### Abstract

**Background:** Acromioclavicular (AC) joint injuries constitute about 9% of all shoulder injuries. AC joint dislocation is a prevalent injury frequently affecting young athlete particularly those involved in contact sports, kabaddi, hockey and football. High grade dislocations if left untreated will always cause a painful joint astrength in the affected shoulder. **Materials and Methods:** It's a prospective cohort study conducted at tertiary care teaching hospital, gems, ragolu, srikakulam, India during the period of 2017- 2020. This fixation procedure was performed in 20 patients (14 male, 6 female). The dominant limb was involved in 14 of 20 cases. **Result:** in our study we had 20 patients, among them 14 were males dominant side shoulder was involved in 14 patients average age of patients included in the study 37.55 yrs, average duration at presentation 3.05 days. At 6 weeks, mean score was 18.2 At 1 year 65% had excellent function 20% good ,15% fair ,5% poor function noted. **Conclusion:** Arthroscopic fixation of ac joint dislocation with dog bone button technique has advantage of minimally invasive simultaneous evaluation and management of intraarticular pathology, no need for implant removal, early mobilisation, reduced wound complications hence we conclude it as better option for dealing ac joint dislocations.

## INTRODUCTION

Acromioclavicular (AC) joint injuries constitute about 9% of all shoulder injuries. AC joint dislocation is a prevalent injury frequently affecting young athlete particularly those involved in contact sports, kabaddi, hockey and football —are at an increased risk.<sup>[1]</sup> It can also result following accidental fall or road traffic accidents. They can result from multiple causes, ranging from a simple fall to high-energy trauma, most commonly result from a direct force to the acromion with the arm in an adducted position. Most of them sustain high grade injuries necessitating surgical treatment to allow them to return to their sport activities. High grade dislocations if left untreated will always cause a painful joint and significant loss of strength in the affected shoulder.

The acromioclavicular (AC) and the coracoclavicular (CC) ligaments stabilize the AC joint and resist translation and rotation in multiple planes when combined with glenohumeral

motion. Stability in the anterior-posterior plane is provided by the acromioclavicular ligaments, which are thickenings of the joint capsule, with the superior ligament being the strongest. Superior-inferior stability is maintained by the trapezoid and conoid coracoclavicular ligaments.<sup>[2]</sup> Thus stability of the AC joint is primarily dependent on the AC and CC ligament complexes. In cadaver dissections, Rosenørn and Pedersen found that if the acromioclavicular ligament, the joint capsule, and trapezius and deltoid muscles were cut, proximal displacement of the clavicle ranged from 0.5 to 1.0 cm. More important, considerable anteroposterior instability also was present when the acromioclavicular ligament and joint capsule were sectioned. If, in addition to these structures, the coracoclavicular ligaments also were divided, the superior clavicular displacement ranged from 1.5 to 2.5 cm.<sup>[3]</sup> This indicates the severity of injury correlates with displacement of clavicle in turn determines the grade of dislocation. Hence the

necessity for near anatomical reconstruction surgery required for AC joint injury.

Recent improvements in understanding the biomechanics and anatomy of the AC joint have led to an evolution in treatment techniques. Many surgical techniques have been described for the treatment of AC joint injuries, but none of them is the gold standard. Application of dog bone button technique arthroscopically shows that if the joint is reduced acutely and retained as reduced during the healing period, the natural ligaments will heal repairing the stability of the AC joint.<sup>[4,5]</sup>

Purpose of this study is to evaluate functional outcome of acute AC joint dislocations treated with arthroscopic Dog button technique with respect to

1. Pain
2. Range of movements
3. Return to activity, pre injury level of function

## MATERIALS AND METHODS

It's a prospective cohort study conducted at tertiary care teaching hospital, gems, ragolu, srikakulam, India during the period of 2017- 2020. This fixation procedure was performed in 20 patients (14 male, 6 female). The dominant limb was involved in 14 of 20 cases.

Physical examination may reveal abrasions of the shoulder and prominence of the distal clavicle as a result of inferior displacement of the scapula. Palpation of the AC joint will reveal tenderness, and shoulder range of motion is typically limited by pain. Motions that result in AC joint loading, such as cross body adduction, may exacerbate symptoms. A thorough upper extremity evaluation was performed to identify additional injuries. Intra-articular injuries<sup>4</sup> (eg, rotator cuff and labral tears) and shoulder girdle and thorax injuries (eg, coracoid fracture, rib fractures, pneumothorax, sternoclavicular joint injuries, floating shoulders, brachial plexus injuries, and scapulothoracic dissociations) have been reported with ac joint dislocation.

Standard anteroposterior, and axillary radiographs were obtained in any patient with a suspected shoulder injury. The axillary view is useful to visualize the degree of posterior displacement of the clavicle. Weighted stress views were not used as they are painful. Although MRI is shown to be superior<sup>5</sup> in evaluating the injury it could not be done in all cases due to cost constraints. We used Rockwood and Green classification for classifying AC joint dislocation.<sup>[6]</sup>

### Inclusion Criteria

All patients with type 3 and above types of AC joint dislocation (isolated injury of the shoulder)

Aged 18 years or above

Presenting within 2 weeks from the date of injury

### Exclusion Criteria

Open injuries and with associated neurological injury

Patients with known pre-existing shoulder pathology  
Patients who had undergone previous shoulder surgery (arthroscopic/open procedure)

### Procedure

Patient in beach chair position under a general anesthesia, supplemented with a scalene block (if desired). A 30° arthroscope is introduced into the glenohumeral joint via a standard posterior portal. A diagnostic evaluation of the intra articular pathology was done in all cases. An anterolateral portal is created. An 8.25 mm cannula is inserted through the Anterolateral portal. A shaver and/or RF electrocautery probe is used through the anterolateral portal to open the rotator interval and expose the coracoid. The coracoid exposure is completed along the inferior border of the coracoid all the way to the base. A low anterior portal lateral to the coracoid is created. A 70° arthroscope in the anterior portal will enhance arthroscopic visualization of the base of the coracoid. Alternately, we can use a 30° arthroscope through the Anterolateral portal to visualize the entire coracoid base. Anterolateral portal will be the primary working portal for the entire procedure and the anterior portal will be visualizing portal. Through the anterolateral portal, the appropriate AC Guide under the coracoid base is placed and the clavicle and coracoid tunnels drilled using the 3 mm Cannulated Drill.

The trocar from the drill is removed and the Suture Wire Loop is passed through the drill cannulation loop first and retrieved through the low anterior cannula. The Cannulated Drill is removed, leaving only the wire in the tunnels. The limbs of a FiberTape and a TigerTape are clipped into the slots of a Dog Bone Button so that the tapes form a U-shape. Slide the button to the base of the tapes. The tapes should wrap around the laser line ensuring that the concavity of the button will sit against the base of the coracoid. The tails of the FiberTape and TigerTape are loaded through the Suture Wire Loop and the tails pulled up through the coracoid and clavicle tunnels. A grasping instrument is used to turn the button sideways and pushed through the PassPort Button Cannula to Seat the Dog Bone Button at the base of the coracoid. The concavity should seat against the coracoid and the orientation line should be in line with the arch of the coracoid. A second Dog Bone Button is clipped onto the suture limbs exiting the clavicle. The concavity should face the clavicle and the orientation line should be in line with the axis of the clavicle. The AC joint is reduced and like FiberTape limbs tied over the button with four alternating half-hitches. The AC joint reduction checked after tying the first knot and then the second FiberTape knot tied. The suture limbs are cut to complete the repair.

Intra-operative satisfactory reduction and fixation were confirmed both clinically and radiologically with the x-ray image intensifier. Postoperative radiographs performed at immediately after surgery and 6 weeks, 3 months, 6 months and 1 year. Post

op shoulder was immobilized for 2 weeks and followed by active assisted mobilization upto 90 degree for 2 weeks and gradually increasing range of motion with strengthening exercises.

Patients were assessed at the end of 6 weeks, 3 months, 6 months and 1 year with radiological evaluation and functional outcome of the shoulder joint. Constant Murley score and UCLA scores were used to assess the function.

## RESULTS

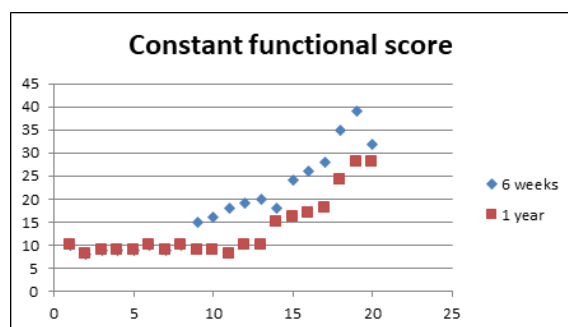
In our study we had 20 patients, among them 14 were males. Dominant side shoulder was involved in 14 patients. Average age of patients included in the study was 37.55 years with 12 patients falling between 20-40 years age group, 8 patients between 41-60 years age group. Average duration at presentation was 3.05 days with 11 patients presenting within 3 days, 5 presented 3-7 days after injury, 4 of them presented between 8-14 days.

4 patients were having type 3 dislocation, 1 patient had type 4 dislocation and 16 were having type 5 dislocation.

Intra operative arthroscopic shoulder examination showed concomitant intra articular pathology in 3 patients. All three of them were noted to have type 1 SLAP tears.

Post-surgery patients were followed up for a period of 1 year with functional and radiological assessments done at 6 weeks, 3 months, 6 months and 1 year. At 6 weeks post-surgery mean functional score was 18.2. Forty percent patients had excellent function, 30% patients had good function, 15% patients had fair function and 15% patients had poor function. Radiological examination of all patients showed good reduction of the AC joint.

Significant improvement in function with gradual return to normal activity was noted during 6-12 weeks following procedure. At one year 13 (65%) patients had excellent functional function, 4 (20%) patients had good outcome, 3 (15%) patients had fair outcome, none of the patients had poor outcome in our study. Radiological examination showed normal alignment in 18 (90%), minimal superior displacement of clavicle in 2 (10%) patients.



None of the patients had any signs of superficial or deep infection in our study. AC joint arthrosis appeared in 2(10%) patients. Osteolysis of the

lateral clavicle affected 1 patient. Heterotopic ossification was evident in 1, appearing most in the region of the CC ligaments. 3(15%) patients had restriction of movements with signs of adhesive capsulitis which resolved with physiotherapy program.

## DISCUSSION

Acromioclavicular joint injuries are one of the common injuries around shoulder joint. Although all injuries may not require surgical treatment, injuries with severe grade i.e grade iii and above require surgical treatment. In Rockwood grade-V injury, AC and CC ligaments and both the origin of the deltoid and insertion of the trapezius are torn, causing extreme instability of the AC joint.<sup>[7]</sup> The objective of surgery is to create an optimal environment for AC ligaments, CC ligaments, and muscle attachments to heal and thus achieve a stable clavicle. Recently, the function of AC and CC ligaments and muscle aponeurosis in clavicular stability has been defined more precisely.<sup>[8-10]</sup>

The literature provides a variety of methods for stabilization of the AC joint. Historically, surgical management includes open reduction, direct repair of the acromioclavicular capsule, and rigid internal fixation of the acromioclavicular joint with wires or screw.<sup>[11]</sup> Weaver and Dunn,<sup>[12]</sup> proposed a technique in which the distal portion of the clavicle is resected and the coracoacromial ligament is transferred from the acromion to the clavicle without internal fixation. This was later modified using autograft augmentation.<sup>[13]</sup> This arthroscopic method has the advantage of being minimally invasive, advantage for simultaneous evaluation and treatment of intra articular pathology, no need for implant removal, early mobilization of shoulder joint, reduce skin or wound complications, and facilitate rehabilitation and earlier return to work or sports activities.<sup>[14-16]</sup> In our study we evaluated the functional outcome in grade 3, 4, 5 dislocations. It was noted that 3 patients were having intra articular lesions associated with this injury. Dominant side was more commonly involved. 70% of patients had good- excellent functional outcome at the end of 6 weeks. Although initial assessment at the end of 6 weeks had 30% patients with fair to poor function most of them had improved at the end of 3 months. Most of them had returned to their pre injury work and activity level at the end of 6 months. At 1 year 85% of patients had good- excellent outcome, 15 % had fair outcome.

There were minimal symptomatic complications with 2 patients having residual tenderness at ac joint who showed signs of arthrosis. Adhesive capsulitis noted in 3 elderly patients resolved with exercises program.

## CONCLUSION

Arthroscopic fixation of ac joint dislocation with Dog button technique can be the better option for treating severe grades of ac joint dislocations. This technique has the advantage of being minimally invasive, simultaneous evaluation and treatment of intra articular pathology, no need for implant removal, early mobilization of shoulder joint, reduced skin or wound complications, and facilitate rehabilitation and earlier return to work or sports activities. It is technically demanding procedure. In our study the limitations were small sample size and it's a prospective cohort study with no comparison group. Further studies involving randomization of samples with larger sample size will be required.

## REFERENCES

1. Agel J, Dompier TP, Dick R, Marshall SW. Descriptive epidemiology of collegiate men's ice hockey injuries: National Collegiate Athletic Association Injury Surveillance System, 1988–1989 through 2003–2004. *J Athl Train.* 2007;42(2):241–248.
2. Debski RE, Parsons IM 3rd, Fenwick J, Vangura A. Ligament mechanics during three degree-of-freedom motion at the acromioclavicular joint. *Ann Biomed Eng.* 2000;28(6):612–618.
3. Rosenørn M, Pederson EB: A comparison between conservative and operative treatment of acute acromioclavicular dislocation, *ActaOrthopScand*45:50, 1974.
4. Pauly S, Gerhardt C, Haas NP, Scheibel M. Prevalence of concomitant intraarticular lesions in patients treated operatively for high-grade acromioclavicular joint separations. *Knee Surg Sports TraumatolArthrosc.* 2009 May;17(5):513-7. Epub 2008 Nov 20.
5. Nemec U, Oberleitner G, Nemec SF, Gruber M, Weber M, Czerny C, Krestan CR. MRI versus radiography of acromioclavicular joint dislocation. *AJR Am J entgenol.* 2011 Oct;197(4):968-73
6. Sanders JO, Lyons FA, Rockwood CA Jr. Management of dislocations of both ends of the clavicle. *J Bone Joint Surg Am.* 1990 Mar;72(3):399-402.
7. Current Concepts Review Management of Acromioclavicular Joint Injuries Xinning Li, MD, Richard Ma, MD, Asheesh Bedi, MD, David M. Dines, MD, David W. Altchek, MD, and Joshua S. Dines, MD *J Bone Joint Surg Am.* 2014;96:73-84
8. Kaisa J Virtanen, Ville M Remes, Ilkka T ATulikoura, Jarkko T Pajarinen, Vesa T Savolainen, Jan-Magnus G Björkenheim & Mika P Paavola Surgical treatment of Rockwood grade-V acromioclavicular joint dislocations. *ActaOrthopaedica*2013; 84 (2): 191–195
9. Galatz L M H, Ronald F Jr., Williams Gerald R Jr. Acromioclavicular joint injuries In: Rockwood and Green's Fractures in Adults 7th edition. (Ed Bucholz R W H, James D, Court-Brown Charles M, Tornetta Paul). Lippincott Williams & Wilkins (LWW). 2009: 1210-24.
10. Fukuda K, Craig E V, An K N, Cofield R H, Chao E Y. Biomechanical study of the ligamentous system of the acromioclavicular joint. *J Bone Joint Surg (Am)* 1986; 68: 434-40.
11. Urist MR. Complete Dislocation of the Acromioclavicular Joint. *J Bone Joint Surg Am.* 1963 Dec;45(Dec):1750-3
12. Weaver JK, Dunn HK. Treatment of acromioclavicular injuries, especially complete acromioclavicular separation. *J Bone Joint Surg Am.* 1972;54(6):1187–1194.
13. Grutter PW, Petersen SA. Anatomical acromioclavicular ligament reconstruction: a biomechanical comparison of reconstructive techniques of the acromioclavicular joint. *Am J Sports Med.* 2005;33(11):1723–1728.
14. Rios CG, Mazzocca AD. Acromioclavicular joint problems in athletes and new methods of management. *Clin Sports Med.* 2008 Oct;27(4):763-88.
15. Salzmann GM, Walz L, Buchmann S, Glabgly P, Venjakob A, Imhoff AB. Arthroscopically assisted 2-bundle anatomical reduction of acute acromioclavicular joint separations. *Am J Sports Med.* 2010 Jun;38(6):1179-87. Epub 2010 May 04.
16. Scheibel M, Dröschel S, Gerhardt C, Kraus N. Arthroscopically assisted stabilization of acute high-grade acromioclavicular joint separations. *Am J Sports Med.* 2011 Jul;39(7):1507-16. Epub 2011 Mar 24.